

BRYAN RADIOLOGY ASSOCIATES

Brazos Valley's leader in advanced diagnostic imaging since 1962
2722 Osler Blvd Bryan, TX 77802; 979-776-8291

MSK Imaging Planes

Ankle: imaging planes

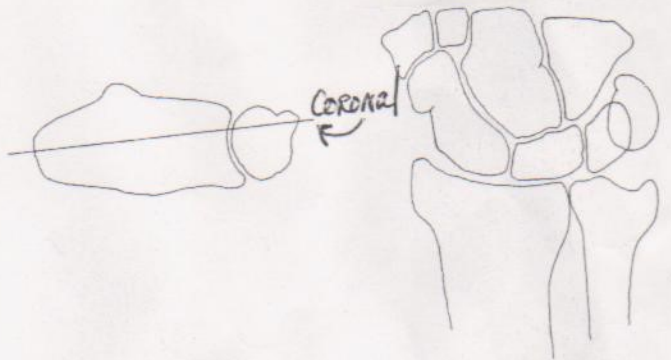
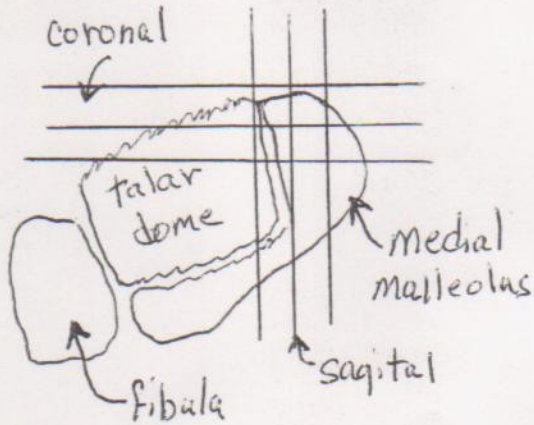


Figure 2-3. Wrist: imaging planes

If the coronal axis is constructed roughly parallel to the volar surface of the radius, both the radial and ulnar styloid processes are visualized on a single image.

Sagittal plane 90° to Coronal plane

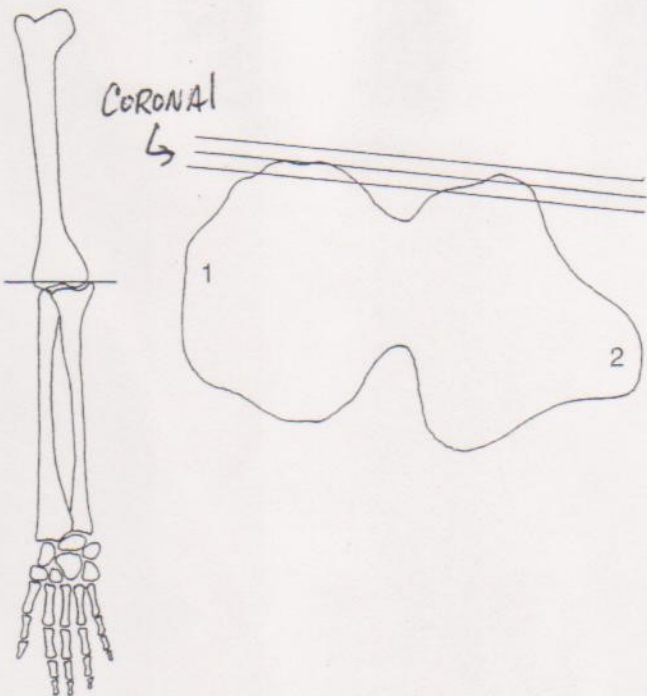


Figure 2-2. Elbow: imaging planes
The axis of the coronal images is shown. 1, capitulum; 2, medial epicondyle.

Sagittal plane - 90° to Coronal

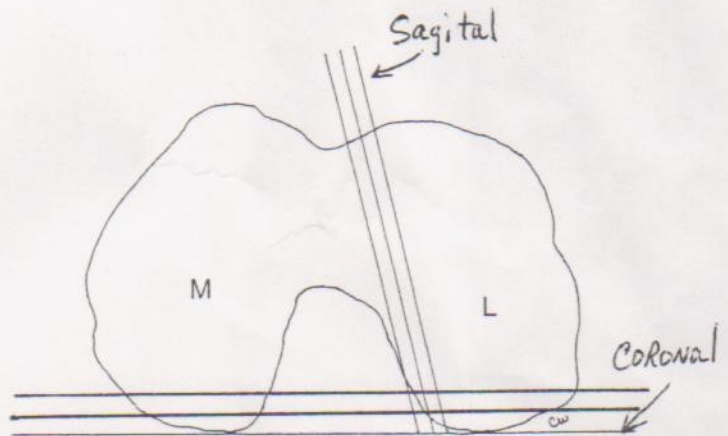


Figure 2-4. Knee: imaging plane

Sagittal oblique images are obtained using an axis oriented about 10 degrees anteromedially. L, lateral femoral condyle; M, medial femoral condyle.

Shoulder Imaging Planes

