

Bryan Radiology Associates
CT orbits W

Last update: 2021-01-03 JN

Setup:

- Tape vitamin E pill to right cheek.
- No bismuth shield.
- Supine, lateral scout from below the mandible through the frontal sinuses

Contrast:

- Inject 100 ml of 320 – 370 mg/dl non-ionic contrast (e.g. Isovue 370 or Omnipaque 350) @ 2 ml/sec with a 90 second delay
- Dose can be decreased for known low GFR.

Scan:

- Range: lower half of maxillary sinuses to upper half of frontal sinuses (fig 1)
- 18 cm DFOV is preferred

PACS Series:

- 1 mm x 1 mm AX Bone **kernel**
- 1 mm x 1 mm AX Soft Tissue
- 1 mm x 1 mm COR Bone **kernel**
- 1 mm x 1 mm COR Soft Tissue
- 1 mm x 1 mm SAG Bone **kernel**
- 1 mm x 1 mm SAG Soft Tissue

See next page for diagram

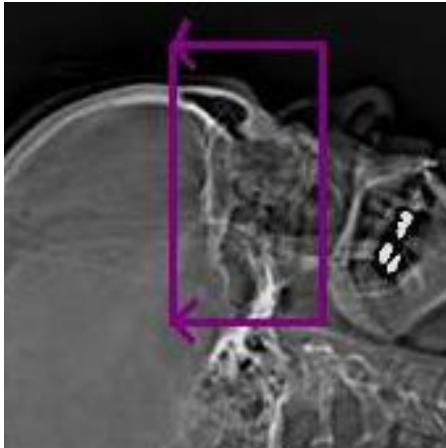


Fig 1

CTDI: ~ 15 mGy

Adapted from ARA