

**Bryan Radiology Associates  
CT orbits WO**

Last update: 2021-01-03 JN

**Setup:**

- Tape vitamin E pill to right cheek.
- No bismuth shield.
- Supine, lateral scout from below the mandible through the frontal sinuses

**Scan:**

- Range: lower half of maxillary sinuses to upper half of frontal sinuses (fig 1)
- 18 cm DFOV is preferred

**PACS Series:**

- 1 mm x 1 mm AX Bone **kernel**
- 1 mm x 1 mm AX Soft Tissue
- 1 mm x 1 mm COR Bone **kernel**
- 1 mm x 1 mm COR Soft Tissue
- 1 mm x 1 mm SAG Bone **kernel**
- 1 mm x 1 mm SAG Soft Tissue

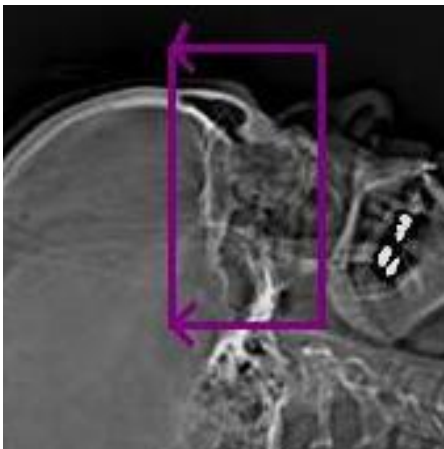


Fig 1

CTDI: ~ 15 mGy

Adapted from ARA